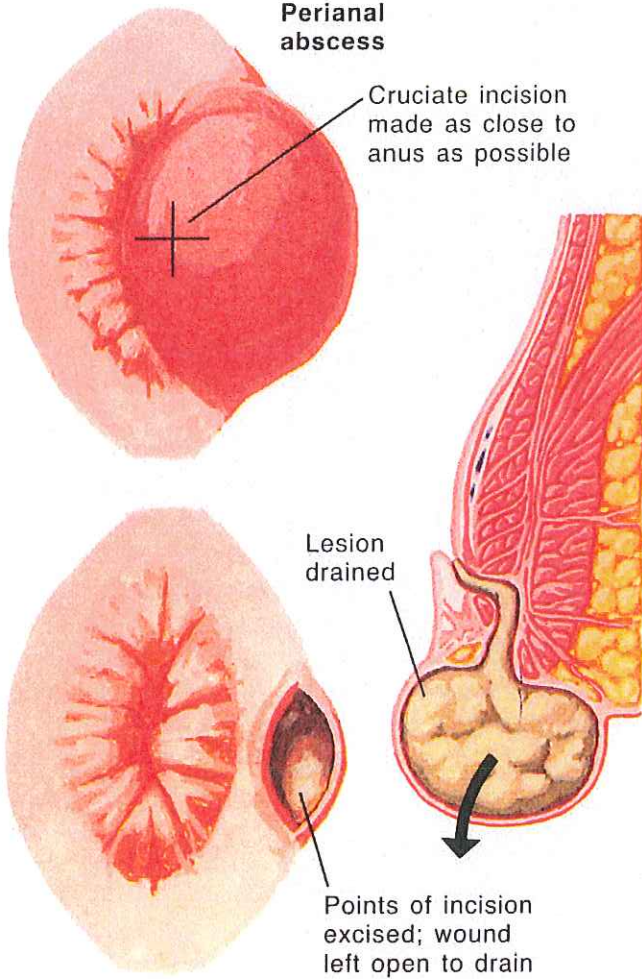
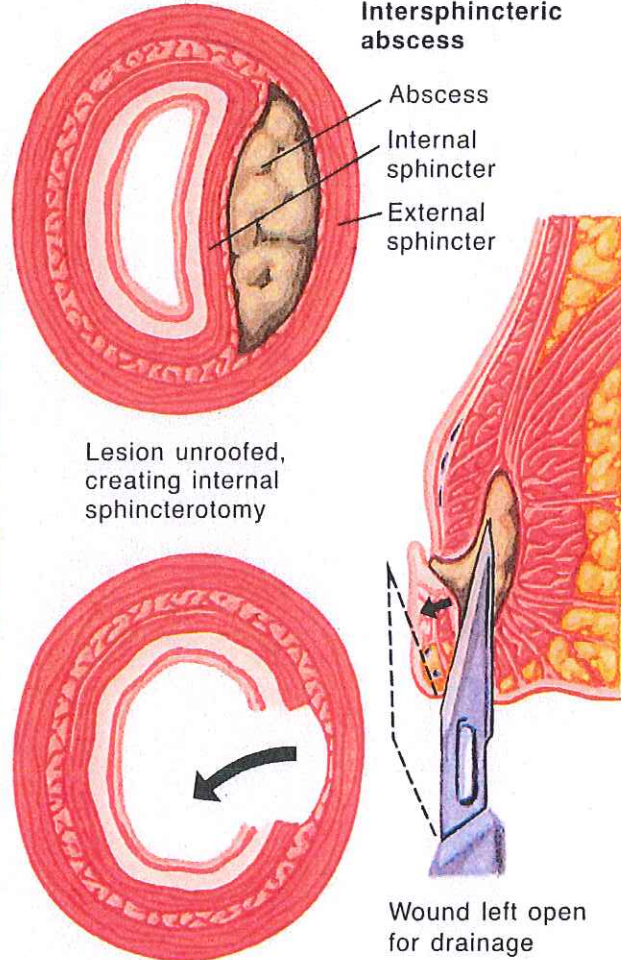


## Surgical Management of Anorectal Abscess

**Perianal abscess**

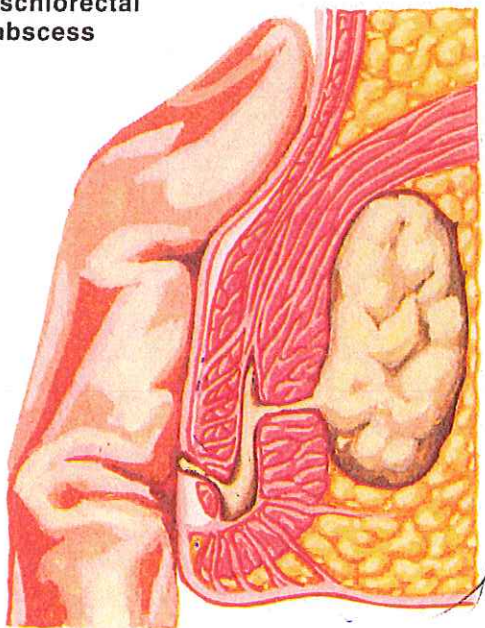


**Intersphincteric abscess**

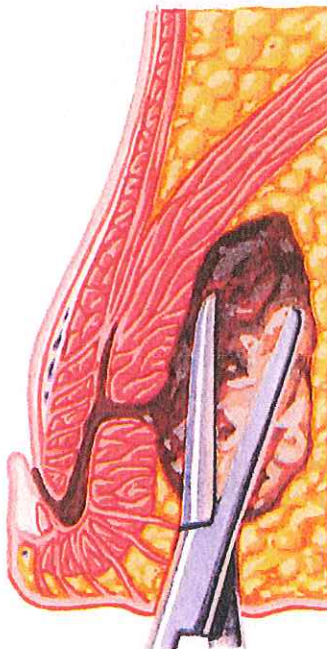


JOHN A. CRAIG, M.D.  
© CIBA

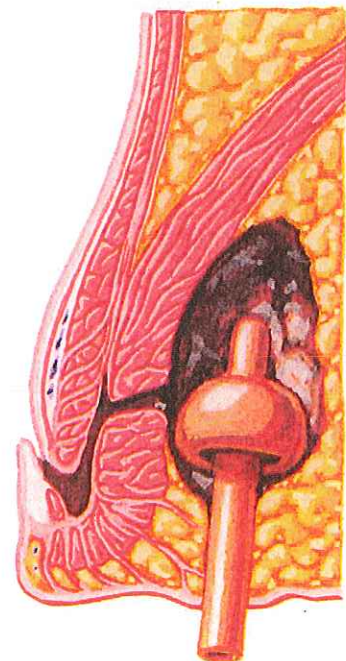
**Ischiorectal abscess**



Ischiorectal abscess may be palpated above anorectal ring, although located inferiorly



Abscess incised and loculations broken down



Mushroom catheter inserted to insure drainage