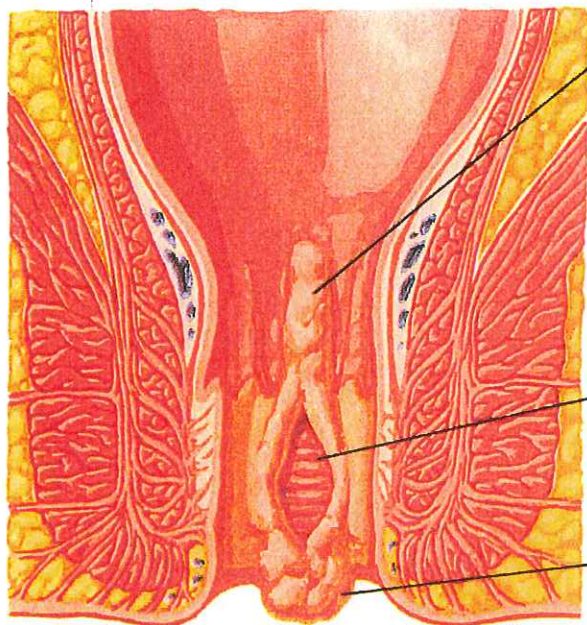


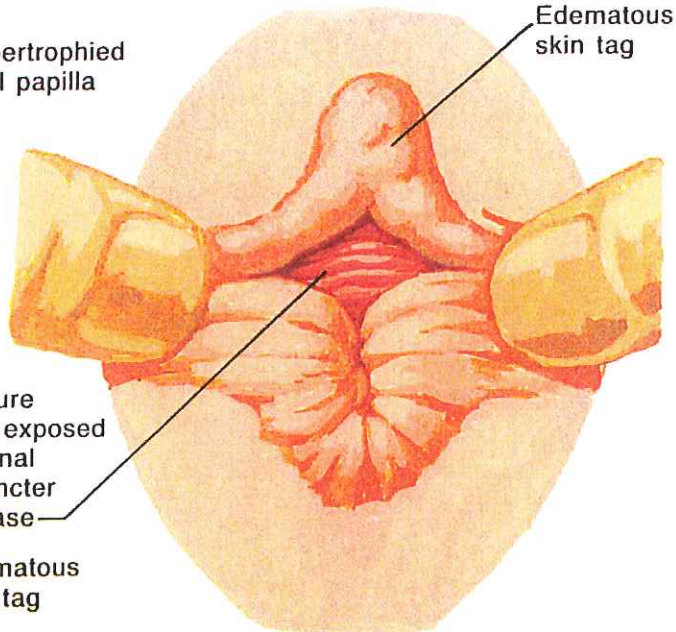
Anal Fissure



Hypertrophied anal papilla

Fissure with exposed internal sphincter in base

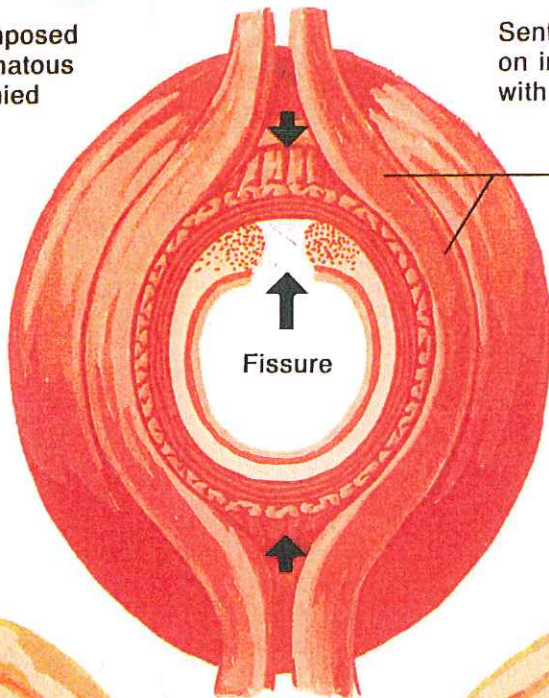
Edematous skin tag



Edematous skin tag

Classic anal fissure composed of fissure, sentinel edematous skin tag, and hypertrophied anal papilla

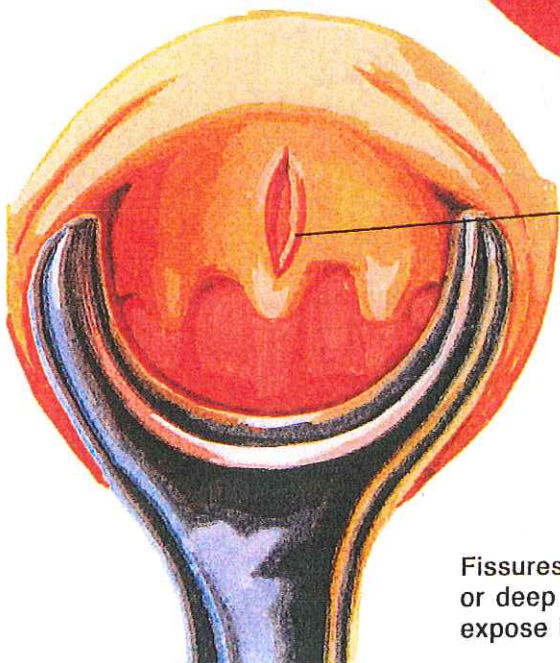
Sentinel skin tag (shows fissure on inspection) may be confused with hemorrhoid



External sphincter

Fissure

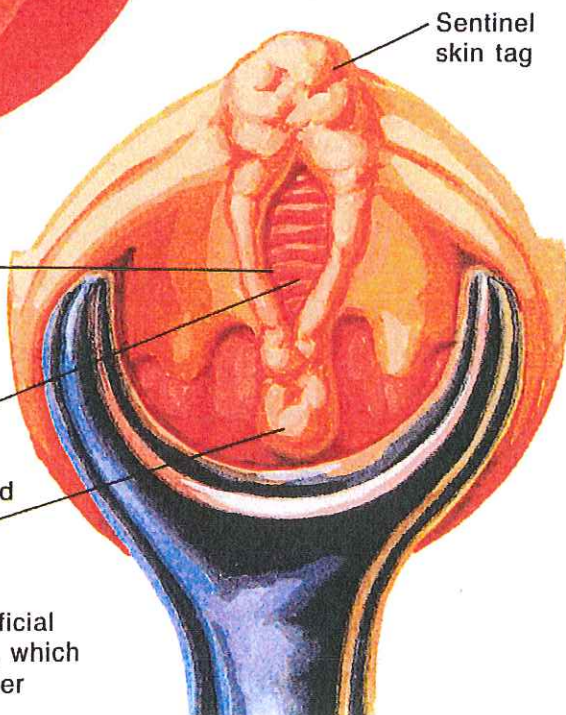
Fissure predilection for midline locus may be related to poor support by external sphincter in these areas



Fissure

Internal sphincter

Hypertrophied anal papilla



Sentinel skin tag

Fissures may be superficial or deep chronic ulcers, which expose internal sphincter