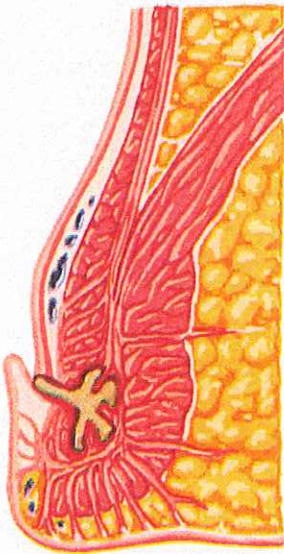
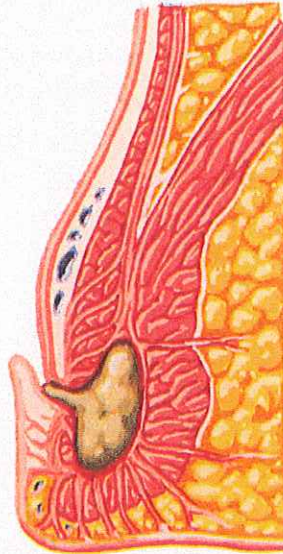


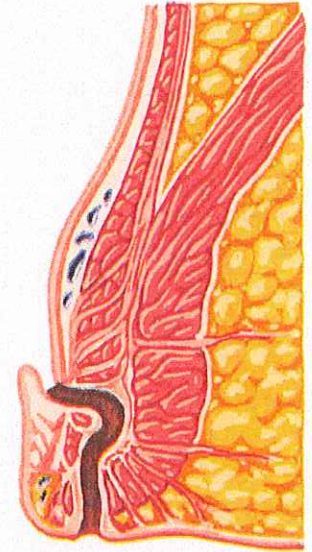
Anorectal Abscess and Fistula in Ano Cryptoglandular Origin Theory



Inflammation of anal crypts (origin)



Acute abscess formation in intersphincteric plane (acute phase)

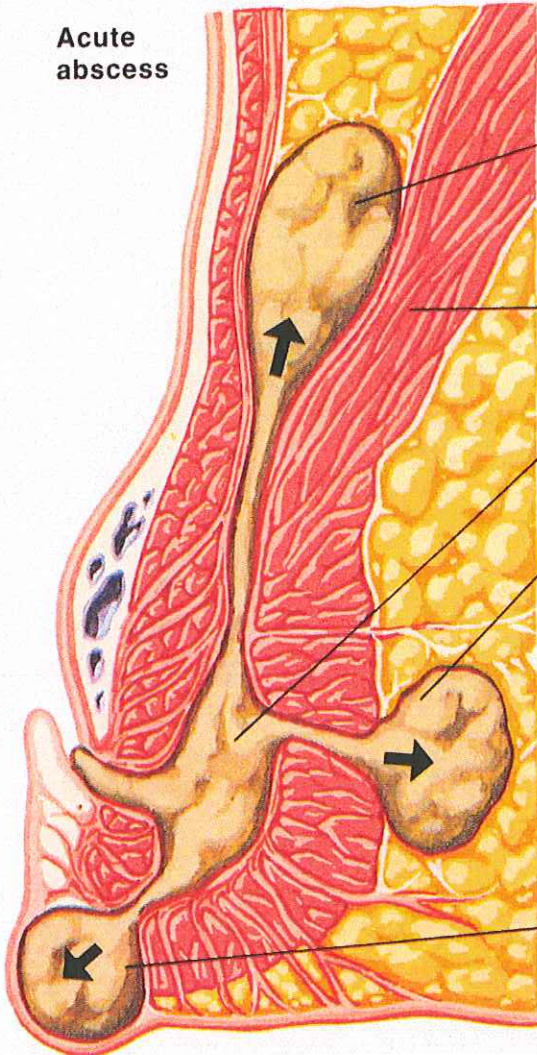


Formation of fistula in ano (chronic phase)

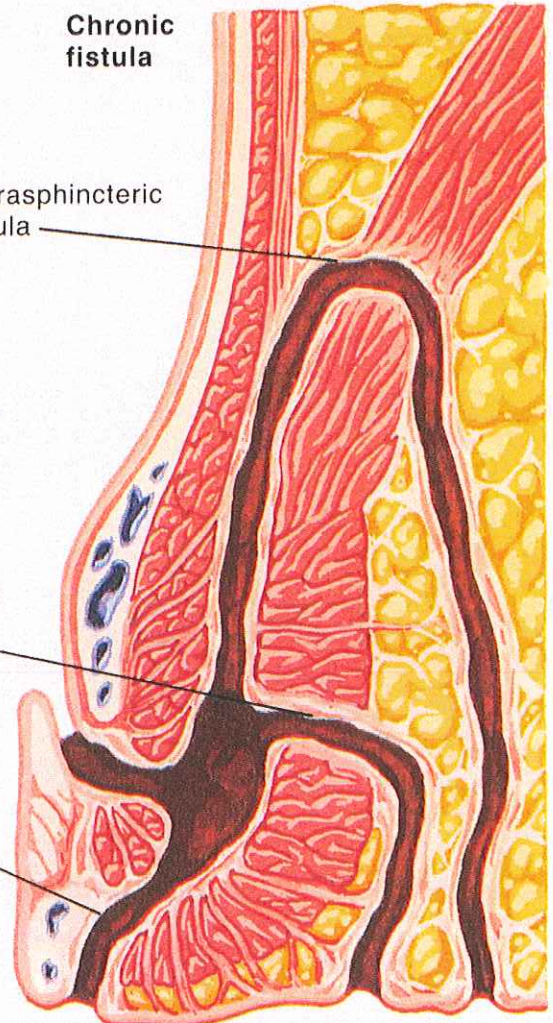
Extension of intersphincteric abscess

JOHN A. CRAIG, M.D.
© CIBA

Acute abscess



Chronic fistula



Supralelevator abscess

Extrasphincteric fistula

Puborectalis muscle

Intersphincteric abscess (origin)

Ischioanal abscess

Transsphincteric fistula

Intersphincteric fistula

Perianal abscess