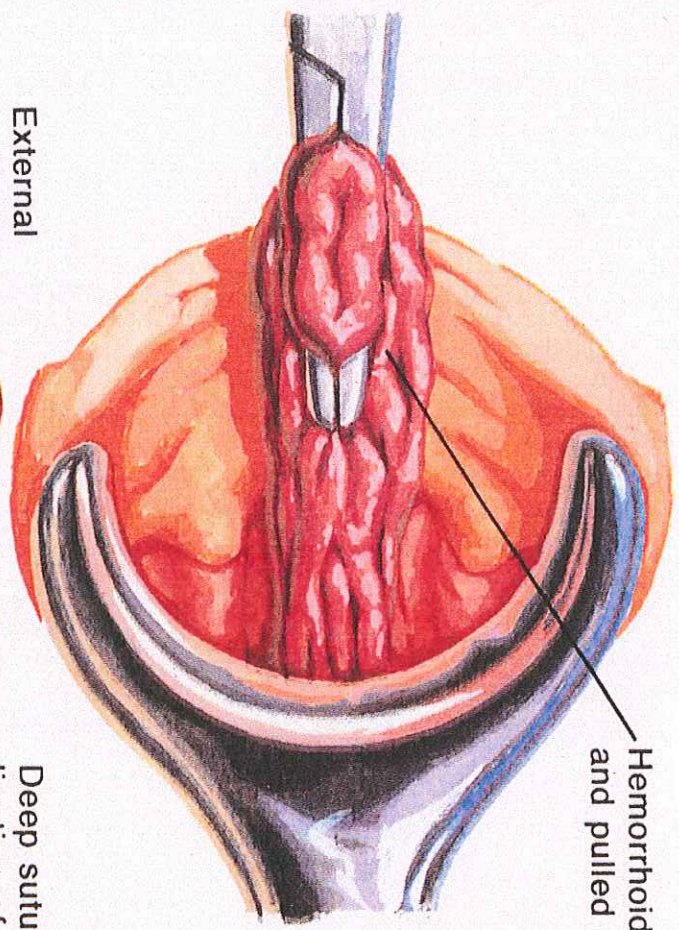
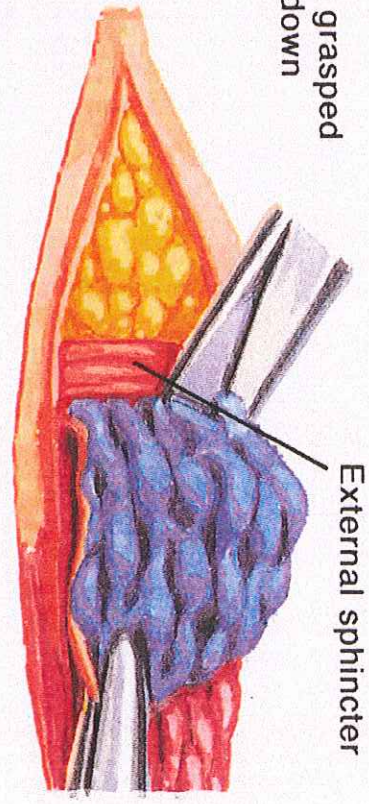


Excision technique

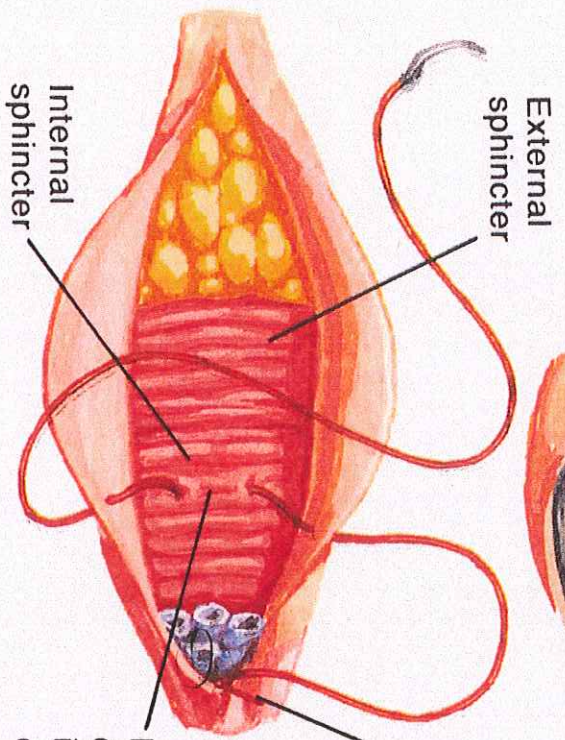


Hemorrhoid grasped and pulled down



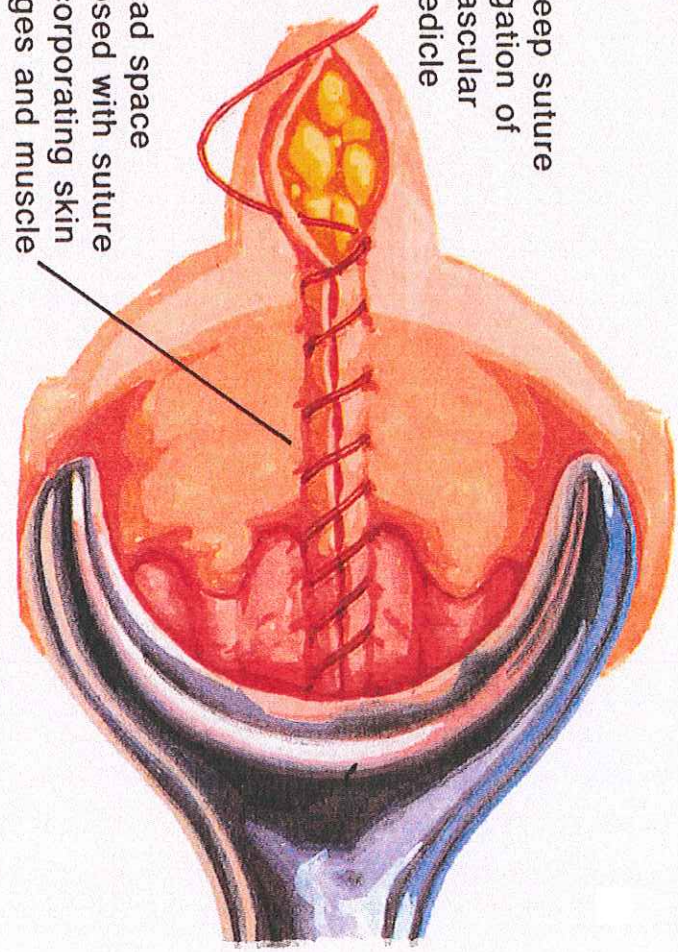
External sphincter

External hemorrhoid dissected free; dissection carried cephalad to free internal portion



External sphincter

Deep suture ligation of vascular pedicle



Dead space closed with suture incorporating skin edges and muscle

Internal sphincter