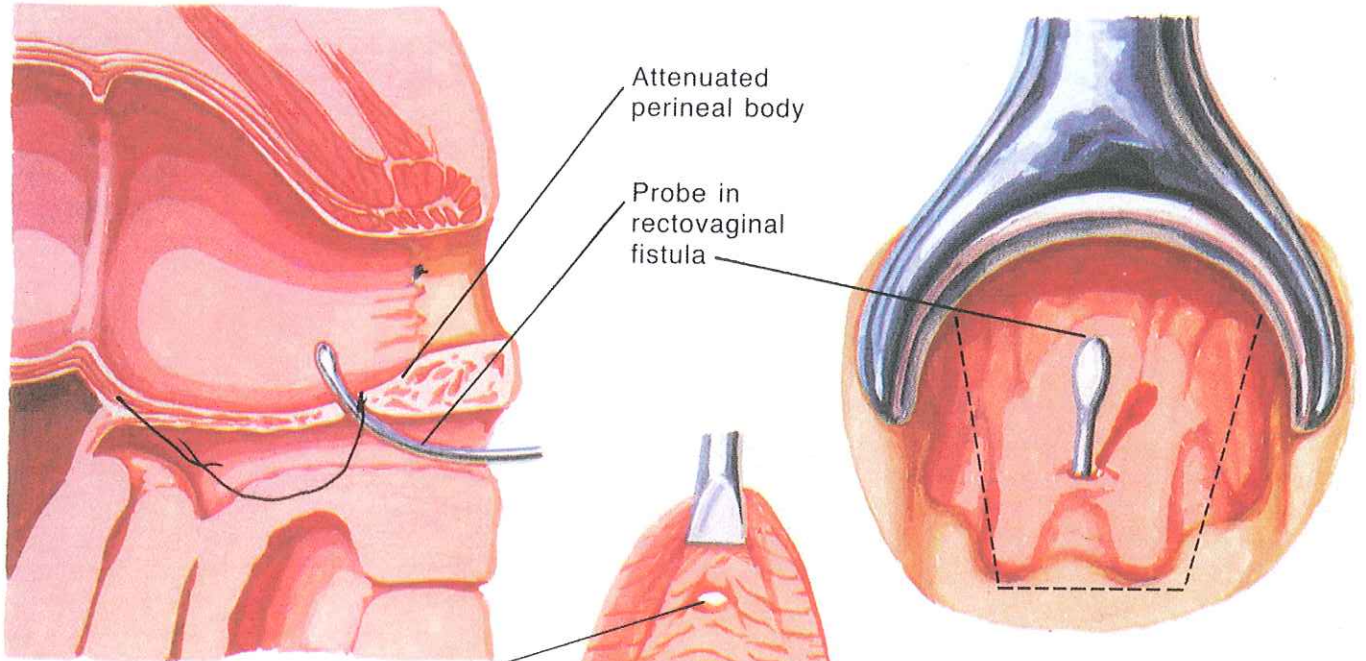
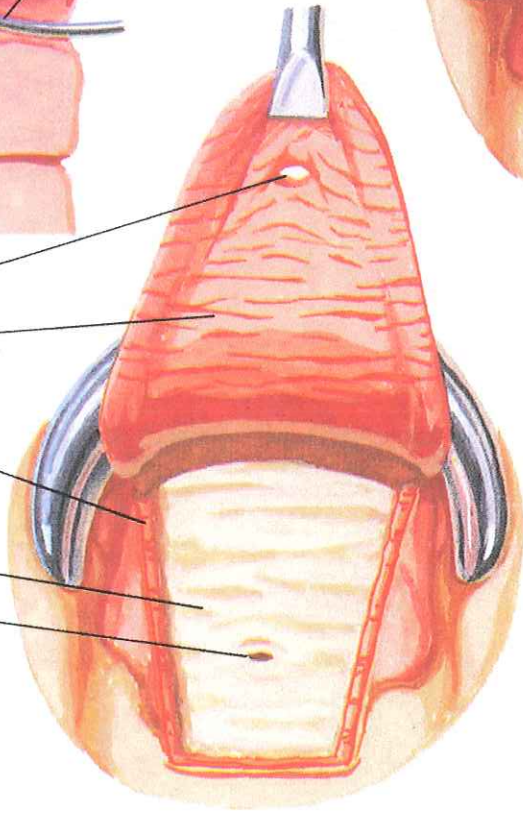


# Rectovaginal Fistula Repair



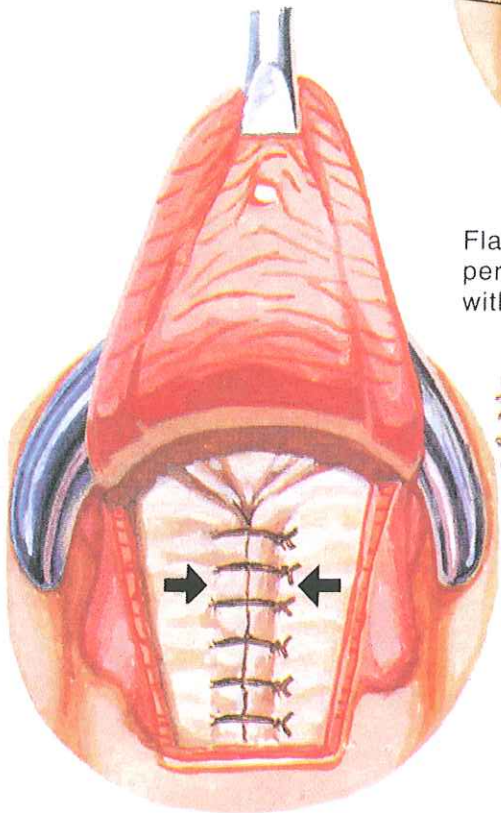
Fistula in flap  
 Flap  
 Cut edge of circular muscle  
 Attenuated perineal body and external sphincter  
 Fistula



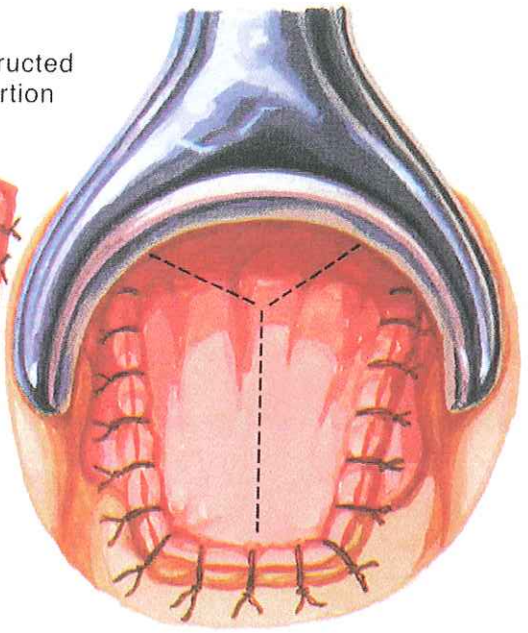
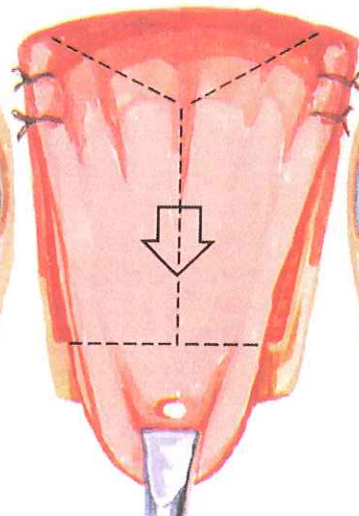
Advancement flap of rectal mucosa, submucosa, and circular muscle elevated from rectal wall

JOHN A. CRAIG, M.D.  
 © CIBA

Flap advanced over reconstructed perineal body; redundant portion with fistula excised



Perineal body reconstructed by plication over fistula



Flap sutured in position with interrupted sutures