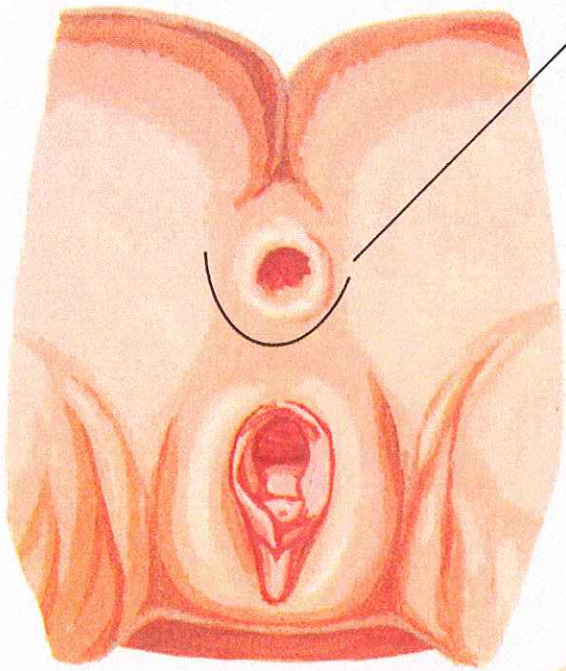
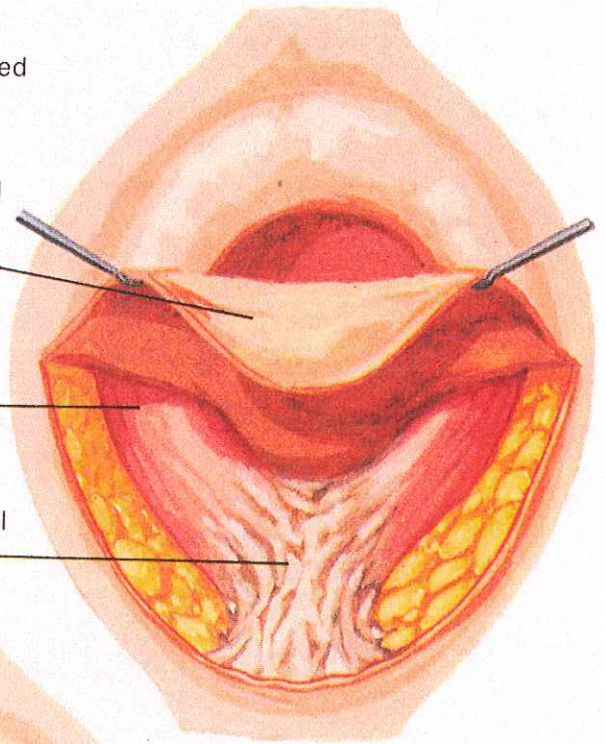


Sphincter Repair Technique



Incision site exposes scarred sphincter

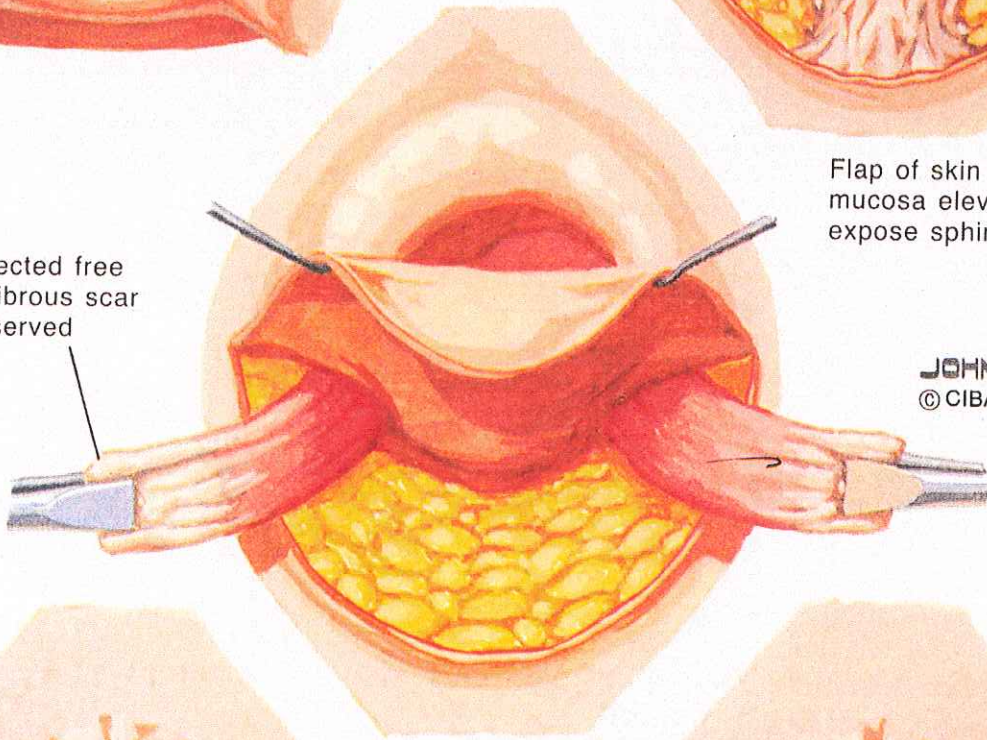


Skin and mucosal flap

Functional sphincter

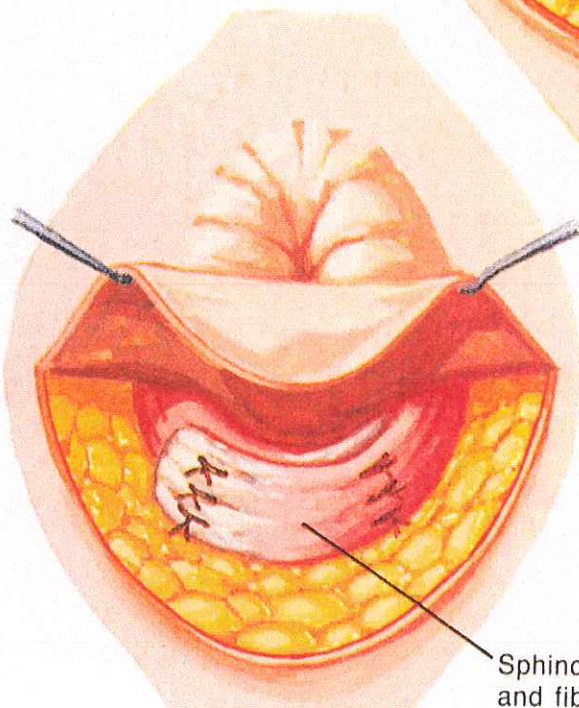
Scarred nonfunctional sphincter

Sphincter dissected free and divided. Fibrous scar should be preserved



Flap of skin and rectal mucosa elevated to expose sphincter

JOHN A. CRAIG, M.D.
© CIBA



Flap repaired and incision closed

Sphincter overlapped and fibrotic end of each

