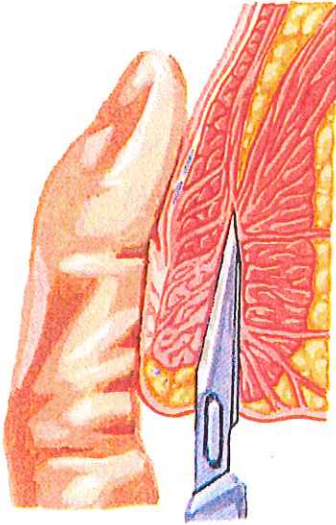


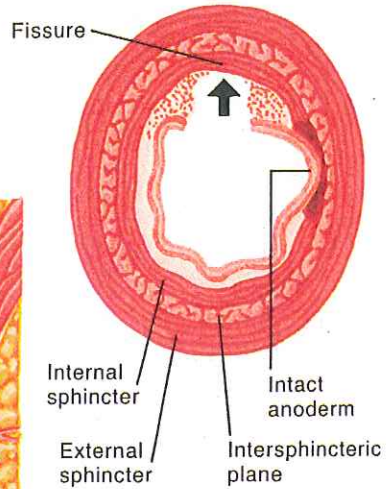
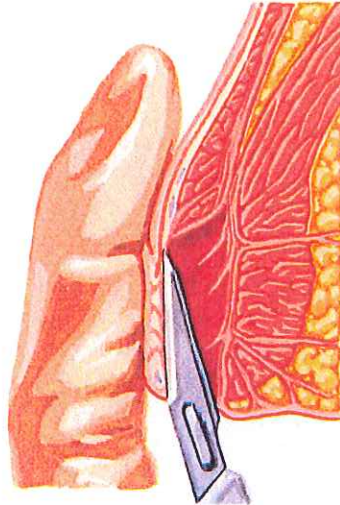
## Lateral Internal Sphincterotomy

### Closed technique



Blade inserted in intersphincteric groove and passed cephalad in intersphincteric plane to level of dentate line

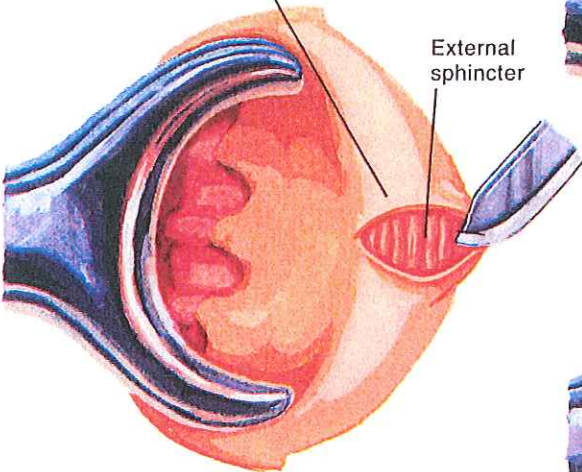
Blade then moved medially, dividing inferior  $\frac{1}{3}$  to  $\frac{1}{2}$  of internal sphincter



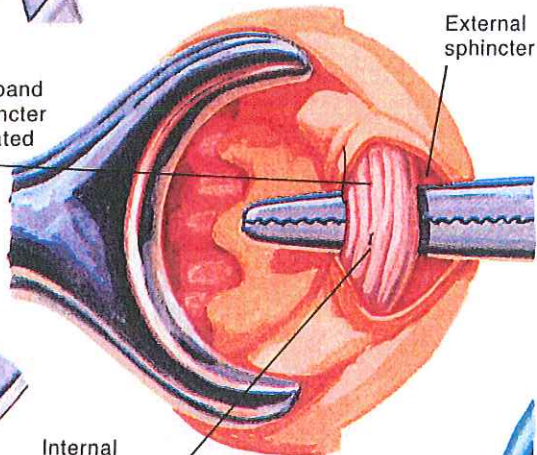
Internal sphincter divided; external sphincter, anoderm, and longitudinal muscle remain intact

### Open technique

Skin incision made external to anal verge



Hypertrophied band of internal sphincter freed and elevated into incision



Internal sphincter divided; wound usually left open for drainage

